

THIRD PARTY COPY

NHS Confidential: Personal data about a patient

TOWNHEAD SURGERY

NEW PATIENT MEDICAL

NAME: DENYS Brown D.O.B: 26-06-70

ADDRESS: 76 Scott Rd TEL No: _____

DATE JOINING: _____ REG DR: _____

CURRENT HEALTH PROBLEMS	
1	Hepatitis C Positive
2	ANXIETY
3	Depression
4	Methadone Depressant
5	Bronchitis

PREVIOUS MEDICAL HISTORY		DATE
1	# 1st Wrist	AS Child
2	DRUG ABUSE	
3		
4		
5		

NO
VPS DOC
IF possible

DRUG NAME	DOSE	FREQUENCY	START	STOP
METHADONE	30mg	DAILY		
DIAZEPAM	5mg	1 TBMAM, 1 PM		
Zopidone	15mg	2 times noct		

HEIGHT (CM)	WEIGHT (KG)	BMI	BP
1-34 C	110 Kg C	32-51	138/77
SMOKING STATUS (PER DAY)	100 CIGARETTES C		
PIPE/CIGAR (AMOUNT)	100 CIGARETTES C		
EX-SMOKER (AMOUNT/DATE)	202 pouch weekly		
ALCOHOL Frequency	NON DRINKER C		
No of Drinks			
Type			
Where			
DIET AWARENESS	NOT GREAT C		
EXERCISE	N/A		
ALLERGIES	NO		

VERIFY
IID <60
IID >60
C/V DISEASE
NONE OF THE ABOVE

LAST TETANUS VACCINE	AT School	DATE
LAST POLIO VACCINE	u c	
LAST CERVICAL SMEAR	N/A	

ACTION	YES	NO	COMMENTS
TETANUS BOOSTER GIVEN		✓	
POLIO BOOSTER GIVEN		✓	
REFER FOR SMEAR TEST		✓	
REFER TO DOCTOR (REASON)	✓		Prescriptions
REFER TO OTHER (SPECIFY)		✓	

C:/MSWORD/LISA/NPMED.DOC 04/02/97

NHS Confidential: Personal data about a patient

Carers Consent Form

Name and address of carer	Name and address of person being cared for
Contact no.	Contact no.
Relationship to person being cared for	Relationship to carer
Is carer registered with this practice?	Is person being cared for registered with this practice?

By completing this form you are giving us your consent and the consent of the other party to add these details to our records

Signature of person completing form.....

Date form completed.....

For Office Use

On completion this form should be forwarded to the Computer Department for updating our Gpass system

SDM PC c:\my documents\service development\carer consent form

1 July 2004

Scanned Document

13-May-2026 AC

Additional:Scanned Document

Filename: Denys Brown 1-4.pdf

Extension:.tif

Pages:

Lesley Douglas (AA Townhead Surgery)

From: Andrea Wardell (AA Townhead Surgery)
Sent: 23 March 2026 15:56
To: aa.Clinical_Specialty_Haematology
Cc: aa.Clinical_Practice_IrvineTownhead_80344
Subject: CHI: 2606703278 DB

Dear Colleague

RE CHI: 2606703278 DB

I would be grateful for your advice on this 55 yr old man who has had a painful lump in his right forearm since July 2025. Initially he presented in Sept 25 stating for several mth he had a painful lump right forearm that had actually reduced in size.

Previous IDVA but stated only injected once in to his forearm and didn't think it had been his right forearm. At that time he had a < 1cm lump soft smooth not red but tender. He contacted us again in Feb 2026 stating that it was getting slightly bigger an still painful.

USS has now confirmed a 7x3x6mm focal echogenic area within a superficial vein and appearances are suggestive of focal thrombus within a superficial vein. The vein is patent and compressible above and below this presumed thrombus.

I phoned the DVT service but they state they only deal with thrombus in legs and advised I seek Haematology advice.

I wonder if you can advise on how I manage this?

Kind regards

Andrea Wardell
GP
Townhead Surgery
IRVINE

NHS Confidential: Personal data about a patient

University Hospital Crosshouse
 Medical Imaging Department
 Kilmarnock Road
 Crosshouse
 KA2 0BE



Diagnostic Imaging Report

CHI No. : 2606703278	Referrer Clinician: Andrea Wardell (GP Townhead)
Patient Name : Brown, Denys	Specialty : General Practice
Patient Address : 124c Montgomery Street Irvine	Address : Townhead Surgery 6-8 High Street Irvine
DOB : 26/06/1970	Ward/Clinic : KA12 0AY GP
Gender : Male	Attendance No. : 51611351

Examination(s) : US Soft tissue	Exam Date : 19 March 2026
Accession(s) : AA15161135101	Report Date : 19 March 2026

Authorised

Patient Name: Denys, Brown
 Patient Address: 124c Montgomery Street, KA12 8PW
 DOB: 26/06/1970
 Patient ID: 2606703278
 Accession Number: AA15161135101
 Referring Cons: Andrea Wardell (GP Townhead)
 Referring Dept: GP
 Visit Type: GP
 Site: University Hospital Crosshouse

51611351 19/03/2026 US Soft tissue

Clinical Indications

Painful 2cm lump right forearm. Firm. Increasing in size was 0.5mm in Sept 25 ? pathology

Report

Ultrasound right forearm
 Longitudinal and transverse scanning carried out in the area of concern as demonstrated by the patient.
 There is a focal echogenic area measuring approximately 7 x 3 x 6 mm demonstrated within a superficial vein in the symptomatic area.
 Ultrasound appearances are suggestive of focal thrombus within a superficial vessel. The vein is patent and compressible above and below this presumed thrombus.

Wilson, Claire (Sonographer)

[END REPORT]

Reported by	Wilson, Claire (Sonographer)
Second Reporter	Keegan, Emma (Sonographer)
Authorised by	Keegan, Emma (Sonographer)

NHS Confidential: Personal data about a patient

Mental Health Services

Addictions
 Caley Court Resource Centre
 Moorpark Road West
 Stevenston
 KA20 3HU
www.nhsaaa.net

**CLINICAL IN CONFIDENCE**

Dr AF Wardell
 Townhead Surgery
 6/8 High Street
 Irvine
 Ayrshire
 KA12 0AY

Clinic Date: 26/02/2026
 Date Dictated: 04/03/2026
 Date Typed: 12/03/2026
 Our Ref: CVW/NS
 Enquiries to: Anne Caldwell
 Tel No: 01294 476000

Dear Dr Wardell,

DENYS BROWN

**124C MONTGOMERY STREET, IRVINE, AYRSHIRE,
 KA12 8PW**

CHI No: 2606703278

Diagnosis: 6C43.2 – Opioid Dependence Syndrome

Psychiatric Medication: Prescribed by Addiction Services
 Methadone 70ml, daily, weekly dispense
 Diazepam 30mg, daily, weekly dispense

Prescribed by General Practitioner
 Quetiapine 200mg, daily
 Pregabalin 150mg three times daily

Recommendations/Plan:

1. No change to medication
2. Ongoing support from key worker
3. Outpatient clinic review in four months

I reviewed Mr Brown via telephone on the 26th February 2026. This was changed from a face to face appointment at short notice due to illness on the writer's part and Mr Brown was happy to be reviewed by telephone today. He reported stability on his prescribed medication and denied any illicit drug use. He has made some reductions to his Methadone dose from 80ml. He continues to use Cannabis occasionally and did not wish to make any changes to this at the moment. He spoke of losing his partner, Nicola, in the summer of last year and he was allowed some time to reflect on how he has been coping with this. He appears to have good support from his family and spends a lot of time with them. Generally, I had no concerns regarding his mental health, based on the presentation on the phone today, and his description of his mood. He has some physical health issues including COPD but did not describe any acute changes.

www.nhsaaa.net

NHS Confidential: Personal data about a patient

I did not make any changes based on my telephone review today but I will appoint Mr Brown for a face to face review in the near future. In the meantime he will continue to be supported by his Key Worker.

Yours sincerely,

Authorised on 12/03/2026 14:41:45 by C Woolston (North).

DR C WOOLSTON
Consultant Psychiatrist
NHS Addiction Services (North)

Hannah Morrison
NADARS Addiction Support Worker
Caley Court Resource Centre
Moorpark Road W
Stevenston
KA20 3HU

THIRD PARTY COPY

www.nhsaaa.net



NHS Confidential: Personal data about a patient

Lesley Douglas (AA Townhead Surgery)

From: Nicola Cheney (AA NADARS)
Sent: 17 October 2025 15:25
To: aa.Clinical_Practice_IrvineTownhead_80344
Subject: Patient Confidential

Follow Up Flag: Follow up
Flag Status: Flagged

Hi

I saw Denys Brown CHI: 2606703278.

He reports that he is frequently forgetting to take his medication & was wondering if he could possibly have a dossett box arranged?

Thanks

Nicola

Nicola Cheney
Community Health Addiction Nurse
North Ayrshire Drug & Alcohol Recovery Service North Ayrshire Health & Social Care Partnership Caley Court
Resource Centre Moorpark Road West Stevenston
KA20 3HU
Tel:- 01294 476000
Mobile:-07483167038

The information contained in this e-mail is intended only for the named recipient(s). If you are not the intended recipient you must not copy, distribute, or take any action or place reliance on it. If you have received this e-mail in error please notify the sender. Any unauthorised disclosure of the information contained in this e-mail is strictly prohibited

NHS Confidential: Personal data about a patient

**Confidential - Clinical
Information**

Department of Respiratory Medicine
University Hospital Crosshouse
Kilmarnock Road
Kilmarnock
KA2 0BE
01563 827907



www.nhsaaa.net

Dr AF Wardell
Townhead Surgery
6/8 High Street
Irvine
Ayrshire
KA12 0AY

Our Ref: SR/CI/
Hospital No:
Ref Date: 11/09/2025
Date Dictated: 11/09/2025
Date Typed: 11/09/2025
Enquiries to: Christine Irvine
Direct Line: 01563 827907
Ext. Number: 27907
Email: Christine.Irvine4@aaapt.scot.nhs.uk

Dear Dr Wardell,

DENYS BROWN DOB: 26/06/1970 CHI No: 2606703278
124C MONTGOMERY STREET, IRVINE, AYRSHIRE, KA12 8PW

Lung function test report from 04th September 2025.

FEV1 3.37 litres (85% predicted) FVC 3.89 litres (77% predicted).
Normal ratio.
There is significant air trapping with increased residual volume.
DLCO 29%.

This would indicate underlying lung parenchymal abnormalities and may be compatible with a diagnosis of either interstitial lung disease, emphysema or a combination.

Yours sincerely

Authorised on 11/09/2025 15:39:06 by Sudipta Roy.

Sudipta Roy
Consultant in Respiratory Medicine
GMC: 4689109

www.nhsaaa.net



NHS Confidential: Personal data about a patient

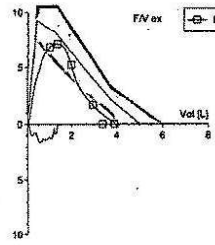
NHS Confidential: Personal data about a patient

NHS Pulmonary Function Laboratory
University Hospitals Ayr / Crosshouse
Ayrshire & Arran

Last Name: Brown Identification: 2606703278 Measurement date: 04.09.25
 First Name: Derys Age: 55 Years Measurement time: 14:55
 Hospital: Tested at Crosshouse Height: 187 cm Measurement device: Vintus...
 Date of Birth: 26/06/1970 Weight: 86.5 kg Ambient air pressure: mmHg 751
 Gender: male BMI: 25 kg/m² Ambient air temperature: °C 26
 Operator: Wm Cassells Physician: Dr Roy S
 Ward: Out Patient

Combined Plethysmography Report

Smoking status: Heavy smoker
Any Info: 7 COPD



SPIROMETRY		Ref	Pre	SR	Pre...
FVC	L	5.00	3.69	-1.83	77.7
FEV1	L	3.99	3.37	-1.16	85.1
FEV1 % FVC	%	77.31	86.94	1.30	112.1
MFEF75/25	L/s	3.86	3.98	0.02	100.5
PEF	L/s	9.27	7.12	-1.77	76.8
FET 100	sec		2.51		
FVC IN	L	5.22	4.32	-6.95	25.4
FIF 50	L/s		1.30		

LUNG VOLUMES

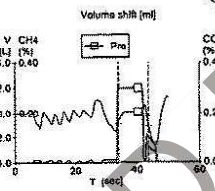
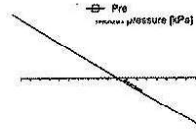
LUNG VOLUMES		Ref	Pre	SR	Pre...
TLC	L	7.86	7.78	-0.11	95.0
VC	L	5.22	2.78	-4.96	53.2
IC	L	3.87	1.76		45.9
FRCpleth	L	3.78	5.01	3.71	158.9
VT	L	0.62	0.76		122.9
ERV	L	1.35	0.00		74.1
RV	L	2.43	5.01	5.28	209.0
RV % TLC	%	35.41	64.32	5.29	181.8

AIRWAYS RESISTANCE

AIRWAYS RESISTANCE		Ref	Pre	SR	Pre...
Raw	kPa(L/s)	0.30	0.10		34.2
Gaw	(L/s)/kPa	3.33	9.76		292.7
sRaw	kPa*s	1.18	0.85		55.6
sGaw	l/(kPa*s)	0.85	1.53		179.8

SINGLE BREATH DIFFUSION

SINGLE BREATH DIFFUSION		Ref	Pre	SR	Pre...
DLCO_SB	mmol/(min*kPa)	11.12	3.26	-5.57	29.3
DLCOcSB	mmol/(min*kPa)	11.12	3.26	-5.57	29.3
VCO_ SB	mmol/(min*kPa*L)	1.41	0.84	-2.63	59.1
VA_ SB (B)	L	7.71	3.90		50.6
VIN L			0.05		
BHT	sec		9.80		



Comment

Unable to do reversibility spirometry, as patient had taken his Ventolin inhaler immediately prior to the test. Poor technique during DLCO.
 No airflow obstruction with static volumes showing very severe air trapping /very severely reduced gas transfer ?accuracy ?technique
 G Toole

(Technician Pre 08.09.2025 08:34)

AA_PFT+SR

08.09.2025

1 / 1

NHS Confidential: Personal data about a patient

**Confidential - Clinical
Information**

Department of Respiratory Medicine
University Hospital Crosshouse
Kilmarnock Road
Kilmarnock
KA2 0BE
01563 827907



www.nhsaaa.net

Dr AF Wardell
Townhead Surgery
6/8 High Street
Irvine
Ayrshire
KA12 0AY

Our Ref: SR/CI/
Hospital No:
Ref Date: 02/04/2025
Date Dictated: 02/04/2025
Date Typed: 09/04/2025
Enquiries to: Christine Irvine
Direct Line: 01563 827907
Ext. Number: 27907
Email: Christine.Irvine4@aaapct.scot.nhs.uk

Dear Dr Wardell,

DENYS BROWN DOB: 26/06/1970 CHI No: 2606703278
124C MONTGOMERY STREET, IRVINE, AYRSHIRE, KA12 8PW

Chest x-ray report from 24th March had shown normal heart size and the lungs are clear.

No evidence of any infection or any other abnormality.

Yours sincerely

Authorised on 09/04/2025 16:43:14 by Sudipta Roy

Sudipta Roy
Consultant in Respiratory Medicine
GMC: 4688109

Denys Brown
124C Montgomery Street
Irvine
Ayrshire
KA12 8PW

www.nhsaaa.net



NHS Confidential: Personal data about a patient

**Confidential - Clinical
Information**

Department of Respiratory Medicine
University Hospital Crosshouse
Kilmarnock Road
Kilmarnock
KA2 0BE
01563 827907



www.nhsaaa.net

Dr DR Renfrew
Townhead Surgery
6/8 High Street
Irvine
Ayrshire
KA12 0AY

Our Ref: SR/CI
Hospital No:
Clinic Date: 20/03/2025
Date Dictated: 20/03/2025
Date Typed: 26/03/2025
Enquiries to: Christine Irvine
Direct Line: 01563 827907
Ext. Number: 27907
Email: Christine.Irvine4@aapct.scot.nhs.uk

Dear Dr Renfrew,

DENYS BROWN DOB: 26/06/1970 CHI No: 2606703278
124C MONTGOMERY STREET, IRVINE, Ayrshire, KA12 9PW

Situation: New referral to respiratory referred by May Walker, Advanced Nurse Practitioner GP surgery.

Background: 54 year old man with respiratory symptoms, breathlessness, lingering cough, several infections.

Smoking status: Current smoker of 4oz tobacco every 2 weeks.

Respiratory symptoms: Breathlessness with exercise tolerance 50m on the flat, recurrent cough with production of greenish sputum.

Current medications: Methadone, Quetiapine, Salbutamol inhaler, Incruse Ellipta, Diazepam, Mebeverine, Meloxicam.

Clinical assessment:
On examination, his oxygen saturation was 90% and his body weight 99.2kg. Chest auscultation revealed moist crackles in the left lung base and around the axilla.

Further investigations:
Chest x-ray in clinic and pulmonary function tests.

Further intervention:
As I see this gentleman's main issue is smoking related lung disease, likely COPD.

www.nhsaaa.net



NHS Confidential: Personal data about a patient

The most effective intervention is smoking cessation and I have spoken to him about this today.

Hi other conditions include opioid dependence, sedative dependence which could clearly add to his symptoms.

Follow up:

This has not been arranged, but I shall be in touch with results of his lung function and further recommendation as appropriate.

Yours sincerely

Authorised on 26/03/2025 14:00:17 by Sudipta Roy.

Sudipta Roy
Consultant in Respiratory Medicine
GMC: 4688109

THIRD PARTY COPY

www.nhsaaa.net



NHS Confidential: Personal data about a patient

Brown, Denys (Mr)

CHI Number 2606703278

Date of Birth 26-Jun-1970 (54y)

Sex Male

Addictions v4 Contact Record**Date of Activity** 23 December 2024 13:31 by Roseann Russell**Status** Closed**Centre of Care** North Drug & Alcohol Rec Serv**Contact details****Attendance**

Cancelled

Contact method

Face to face

Contact type

Review contact with client

Status of contact

Routine

Main substance use

Drug

Treatment Package

Physical and Social Health Support

Actions undertaken**Contact outcome****Intervention outcome****Summary of contact/details****Summary of contact/details**

Dear Dr. McNair,

DENYS BROWN 124C MONTGOMERY STREET, IRVINE, KA12 8PW
CHI No: 2606703278Diagnosis: 6C43.2 -- Opioid Dependence Syndrome
6C44.2 -- Sedative Dependence Syndrome (Benzodiazepines)Psychiatric Medication: Prescribed by Addiction Services
Methadone 85ml, daily, weekly dispense
Diazepam 30mg, daily

Printed 06/01/25 by Roseann Russell - Staff copy

Page 1 of 2

NHS Confidential: Personal data about a patient

Brown, Denys (Mr)

CHI Number 38087103276

Date of Birth 26-Jun-1976 (54y)

Sex Male

Prescribed by General Practitioner
Quetiapine 100mg, daily
Pregabalin, dose unconfirmed

Mr Brown made telephone contact with our service to cancel his planned NMP review with myself on 23/12/2024 at 12pm due to being away with relatives.

I will offer a further appointment in the New Year, and his key worker will be available for support.

THIRD PARTY COPY

Printed 06/01/25 by Roseann Russell - Staff copy

Page 2 of 2

NHS Confidential: Personal data about a patient









Personal exercise program

ix thx





NHS Ayrshire & Arran
 University Hospital Crosshouse
 NHS Ayrshire & Arran, Crosshouse, Kilmarnock, KA2 0BE, East
 Ayrshire, Scotland, United Kingdom

Provided by **Lori Mamson**
 Provided for
 Training start date **04/09/2024**

 <small>©Physiotools</small>	<p>Lying on your back with knees together and bent. Slowly roll your knees from side to side keeping your upper trunk still. Repeat <u>10</u> - <u>15</u> times.</p>	 <small>©Physiotools</small>	<p>Lying on your back with knees bent and arms by your side. Rolled up towel between your shoulder blades, pillow under head. Rest for 10 mins allowing shoulder to relax down.</p>
 <small>©Physiotools</small>	<p>Lying on your back with knees bent and arms by your side. Tighten your stomach muscles and press the small of your back against the floor letting your bottom rise. Hold <u>5</u> secs. - relax. Repeat <u>10</u> times.</p>	 <small>©Physiotools</small>	<p>Lying on your back with knees bent. Tighten your stomach muscles by pushing your back down and curving your bottom up - relax. Continue the exercise by pushing your bottom down and tightening your back muscles to arch your lumbar (lower) spine up - relax. Repeat <u>10</u> - <u>15</u> times.</p>
 <small>©Physiotools</small>	<p>Sit on a chair with your fingers clasped behind your neck. Lean the affected part of the thoracic spine against the back of the chair so that the chair supports the lower of the vertebrae to be mobilised. While inhaling push your shoulders over the edge of the chair, at the same time lean back to straighten the spine. Repeat <u>5</u> times.</p>	 <small>©Physiotools</small>	<p>Sit on a stool and practise good posture. First let your back drop and get rounded, then use your back muscles to straighten your back and arch it (not too much). Repeat <u>10</u> - <u>15</u> times.</p>

THIRD PARTY COPY

NHS Confidential: Personal data about a patient

 ©Physio4uk	<p>Sit on a chair with your legs apart and feet firmly on the floor. Cross arms across your front.</p> <p>Twist your upper trunk from side to side. Let your head follow the movement.</p> <p>Repeat <u>5</u> times.</p>	 ©Physio4uk	<p>Sit on a chair with your legs apart.</p> <p>Bend your head and trunk down between your knees rounding your upper body as much as possible. Hold approx: <u>20</u> secs.</p>
 ©Physio4uk	<p>Sit on a chair.</p> <p>raise left knee, extend head back, lower leg lower head.</p> <p>Repeat <u>15</u> times.</p>	 ©Physio4uk	<p>Lying on your back or sitting.</p> <p>Bend and straighten your ankles briskly. If you keep your knees straight during the exercise you will stretch your calf muscles.</p> <p>Repeat <u>15</u> times.</p>

THIRD PARTY COPY

Not Confidential: Personal data about patient

Ayrshire Central Hospital (Irvine)
 Medical Imaging Department
 Kilwinning Road
 Irvine
 KA12 8SS



Diagnostic Imaging Report	
CHI No. : 2606703278	Referrer Clinician: Stephanie McNair (Reg Townhead)
Patient Name : Brown, Denys	Specialty : General Practice
Patient Address : 124c Montgomery Street Irvine AYRSHIRE	Address : Townhead Surgery 6-8 High Street Irvine
DOB : 26/06/1970	Ward/Clinic : KA12 0AY
Gender : Male	Attendance No. : 50899397
Examination(s) : US Abdomen	Exam Date : 02 August 2024
Accession(s) : AA15089939701	Report Date : 05 August 2024
Authorised	
Patient Name: Denys, Brown Patient Address: 124c Montgomery Street, KA12 8PW DOB: 26/06/1970 Patient ID: 2606703278 Accession Number: AA15089939701 Referring Cons: Stephanie McNair (Reg Townhead) Referring Dept: GP Visit Type: GP Site: Ayrshire Central Hospital (Irvine)	
50899397 02/08/2024 US Abdomen	
Clinical indications	
abdominal pain after eating. severe. ? gallstones also constipated may be bowel spasm pain.	
Report	
Technically challenging scan due to patient body habitus - unable to fully assess left lobe of liver. Bowel gas ++	
Given the above limitations, the liver is normal in size and echotexture. No overt focal hepatic abnormality seen. No intra-hepatic duct dilatation. Normal directional flow is observed within the main portal vein.	
The gallbladder is grossly obscured by bowel gas, however as best seen, appears thin-walled with no gallstones. Normal biliary tree.	
Grossly normal ultrasound appearances of the spleen and both kidneys.	
The abdominal aorta and pancreas are obscured.	
No upper abdominal free fluid collections seen.	
Stewart, Karin (trainee Sonographer, RA68457) - still images & report reviews my A. McClymont (Sonographer)	
[END REPORT]	
Reported by	Stewart, Karin (Student Sonographer, RA68457)
Second Reporter	McClymont, A (Sonographer RA68467)
Authorised by	McClymont, A (Sonographer RA68467)

NHS Confidential: Personal data about a patient

Pauline Stewart (AA Townhead Surgery)

From: aa.Clinical_Practice_IrvineTownhead_80344
Sent: 17 June 2024 09:24
To: Christine Irvine (AA Respiratory)
Subject: DB 2606703278

Good morning,

Denys Brown – CHI: 2606703278

With reference to your letter dated 30/05/24, could you please let Dr Roy know that no respiratory referral is required currently.

Yours sincerely,

Dr Step McNair
Townhead Surgery
6/8 High Street
Irvine
KA12 0AY

THIRD PARTY COPY

NHS Confidential. Personal data about a patient.

Ayrshire Central Hospital (Irvine)
 Medical Imaging Department
 Kilwinning Road
 Irvine
 KA12 8SS



Diagnostic Imaging Report	
CHI No. : 2606703278	Referrer Clinician: Stephanie McNair (Reg Townhead)
Patient Name : Brown, Denys	Speciality : General Practice
Patient Address : 124c Montgomery Street Irvine AYRSHIRE	Address : Townhead Surgery 6-8 High Street Irvine
DOB : KA12 8PW 26/06/1970	Ward/Clinic : KA12 0AY GP
Gender : Male	Attendance No. : 51018612
Examination(s) : XR Chest	Exam Date : 10 June 2024
Accession(s) : AA15101861201	Report Date : 18 June 2024
Authorised	
Patient Name: Denys, Brown Patient Address: 124c Montgomery Street, KA12 8PW DOB: 26/06/1970 Patient ID: 2606703278 Accession Number: AA15101861201 Referring Cons: Stephanie McNair (Reg Townhead) Referring Dept: GP Visit Type: GP Site: Ayrshire Central Hospital (Irvine)	
51018612 10/06/2024 XR Chest	
Clinical Indications heavy smoker noisy chest with biltaeral lower zone noises left worse than right wheezy polycythemic ? signs of lung pathology	
Report PA radiograph. Reference is made to previous CT dated 11/01/2021. Rotated film. Even allowing for rotation, normal appearance to the heart size and cardiomeastinal contours. No focal consolidation. No pleural effusion. Very minor linear atelectasis at the right lower zone. Bony thorax intact.	
Kwek, Adriel Ju Wen (Rad.Registrar, 7597317) [END REPORT]	
Reported by	Kwek, Adriel Ju Wen (Rad.Registrar, 7597317)
Second Reporter	Sarker, B (Cons Radiologist 6128563)
Authorised by	Sarker, B (Cons Radiologist 6128563)

Hospital use only	Clinic	Day Date	Time	Hospital No.
-------------------	--------	----------	------	--------------

Transport required?

Unique Care Pathway Number: 101033800958E

REFERRAL LETTER
MEDICAL IN CONFIDENCE

CHI:2606703278

REFERRAL TO	
Respiratory MedicineAQ AA Respiratory	Ethnic Origin (White) Scottish
University Hospital Crosshouse Kilmarnock Road Kilmarnock Ayrshire KA2 0BE	Language interpreter req'd - Religion - Religious Observance - Vision impairment - Hearing impairment - Sign language interpreter req'd. -
Urgency of referral Routine	
Date of referral 02-Aug-2024	
Date submitted 02-Aug-2024	

PATIENT DETAILS		Patient's address
Surname Brown		124c Montgomery Street Irvine KA12 8PW
Forename(s) Denys		
Title -		
Sex Male		
Date of birth 26-Jun-1970		Contact number(s)
CHI no. 2606703278		-

REGISTERED GP DETAILS		Practice address
Name Dr Duncan Renfrew		6/8 High Street Irvine
GMC code 6163146	GP code 21181	
Practice name Townhead Surgery		
Practice code 80344		Contact number(s)
		Voice: 01294 441441 Facsimile: 01294 312832

REFERRING PRACTITIONER DETAILS		Practice address
Name Dr. Duncan Renfrew		6/8 High Street Irvine AYRSHIRE KA12 0AY
GMC code 6163146	GP code 21181	
Practice name Townhead Surgery (80344)		
Practice code 80344		Contact number(s)
		Voice: 01294 441 441

file:///P:/PCTI/DOCMAN7/DATA_S1/Document/DMEDOC01/00018100/01577279.... 13/05/2026

CLINICAL INFORMATION**History of presenting complaint / examination findings / investigation results****Presenting complaint**

Description: see below

Comment: Dictated 30/07/24 ac

I would be grateful if you could see this 54 year old gentleman who has been having respiratory symptoms for over a year. He is feeling breathless which is gradually increasing. It is affecting his daily activities and quality of life. He has a recurrent cough. He has had several infections over the last year. He is a smoker who smokes cannabis and some tobacco, and he has been given a trial of inhalers, with little effect. His breathlessness seems to continue. He has had a recent chest x-ray which was unremarkable, and he has been diagnosed with polycythaemia.

We wonder if in view of the symptoms and fact that his sats are consistently low, between 90-93%, if you would consider seeing him.

Many thanks.

May Walker
Advanced Nurse Practitioner

Examinations and Investigations

Height:	184	-
Weight(kg):	110	-
BMI:	32.49	-
Current smoker :	O/E- sob and cough> 3/12 has had a satisfactory chest xray . Was given saba with min effect , then lama 1/12 ago with very good effect . Sats 93% heavy smoker cannabis and tobacco- TRUNCATED	30-Jul-2024 00:00
Light smoker - 1-9 cigs/day:	Smoker\$.clm - Repeat after an Interval	31-Dec-2009 00:00
Current smoker:	Smoker\$.clm - Repeat after an Interval	23-Nov-2006 00:00
Moderate smoker - 10-19 cigs/d:	Disease: New Patient Townhead, priority=2	31-Aug-2006 00:00
Current smoker:	Smoker\$.clm - Repeat after an Interval	31-Aug-2006 00:00
Teetotalter:	Disease: New Patient Townhead, priority=2	31-Aug-2006 00:00
Avoids even trivial exercise:	Disease: New Patient Townhead, priority=2	31-Aug-2006 00:00

Reason for referral

Care type requested: Out Patient

Expected outcome: Not Specified

Past medical history**Pre-existing conditions**

Description	Laterality	Modifier	Extension	Date of onset	Recorded Date
Query Gallstones	Uncertain	-	re US Abdomen result recd 27/10/17. [Further scan to be done]	20-Oct-2017	20-Oct-2017
Drug addiction	-	-	Disease: New Patient Townhead, Cannabis and diazepam	30-Jul-2002	30-Jul-2002
[X]Assault	-	-	Disease: New Patient Townhead,	10-Jul-2000	10-Jul-2000
Stabbed in fight	-	-	Disease: New Patient Townhead, Left chest wall	10-Jul-2000	10-Jul-2000
Anxiety with depression	-	-	Disease: New Patient Townhead,	05-Jul-2000	05-Jul-2000
Nondependent abuse of drugs	-	-	Disease: New Patient Townhead, Heroin	06-Jun-2000	06-Jun-2000
				30-Jan-	30-Jan-

file:///P:/PCTI/DOCMAN7/DATA_S1/Document/DMEDOC01/00018100/01577279.... 13/05/2026

Drug addiction	-	-	Disease: New Patient Townhead,	1996	1996
Closed fracture of radius (alone), unspecified	-	-	Disease: New Patient Townhead, Left	04-Aug-1982	04-Aug-1982
Acute bronchitis	-	-	Disease: New Patient Townhead, Admitted	25-Feb-1971	25-Feb-1971

Past procedures

Description	Laterality	Modifier	Comments	Date performed	Recorded Date
Medication reconciliation	-	-	Prescribed Elsewhere	02-Sep-2022	02-Sep-2022
Medication reconciliation	-	-	Prescribed elsewhere	07-Jan-2022	07-Jan-2022
Medication reconciliation	-	-	Prescribed elsewhere	07-Jan-2022	07-Jan-2022
Medication reconciliation	-	-	Prescribed Elsewhere	22-Nov-2021	22-Nov-2021
Medication reconciliation	-	-	prescribed elsewhere	18-Nov-2020	18-Nov-2020
Medication reconciliation	-	-	Prescribed elsewhere	20-May-2020	20-May-2020
Medication reconciliation	-	-	Prescribed elsewhere	14-May-2020	14-May-2020
Medication reconciliation	-	-	Prescribed elsewhere	25-Jul-2017	25-Jul-2017
Medication reconciliation	-	-	Prescribe elsewhere	29-Dec-2016	29-Dec-2016
Medication reconciliation	-	-	Prescribed Elsewhere	09-Feb-2016	09-Feb-2016
Medication reconciliation	-	-	prescribed elsewhere	26-Nov-2014	26-Nov-2014
Hepatitis C antibody test positive	-	-	Disease: New Patient Townhead,	28-May-1999	28-May-1999
Detoxification dependence drug	-	-	Disease: New Patient Townhead,	30-Jan-1996	30-Jan-1996

Current medication (Active Repeat medication issued within the last 12 months)

Drug name	BNF code	Formulation	Dosage	Frequency	Course started	Duration	Last Prescribed Date
Incruse Ellipta Dry Powder Inhaler 55 micrograms/dose	-	30 DOSE	ONE PUFF ONCE DAILY	-	11-Jun-2024	-	30-Jul-2024
Lactulose Solution 3.1-3.7 g/5 ml	0106040G0AAAAAA	300 ML	THREE 5ML SPOONFULS TO BE TAKEN TWICE A DAY	-	11-Jun-2024	-	02-Jul-2024
Salbutamol Cfc-free inhaler 100 micrograms/puff	0301011R0AAAPAP	1 INHALER	ONE TO TWO PUFFS TO BE INHALED AS REQUIRED FOR BREATHLESSNESS	-	28-May-2024	-	30-Jul-2024
Omeprazole Capsules (Gastro-Resistant) 20 mg	0103050P0AAAGAG	28 CAPSULE	ONE TO BE TAKEN EACH DAY	-	02-Sep-2021	-	30-Jul-2024
Pregabalin Capsules 150 mg	-	84 CAPSULE	ONE TO BE TAKEN THREE TIMES A DAY	-	29-Jul-2021	-	30-Jul-2024
Mebeverine Hydrochloride Tablets 135 mg	0102000P0AAABAB	100 TABLET	ONE TO BE TAKEN THREE TIMES A DAY 20 MINUTES BEFORE MEALS	-	14-Mar-2019	-	30-Jul-2024
Meloxicam Tablets 15 mg	1001010AAAAABAB	30 TABLET	ONE TO BE TAKEN DAILY	-	03-Jul-2018	-	30-Jul-2024
Quetiapine Fumarate Tablets 200 mg	0402010ABAAADAD	28 tablet	1 Tab DAILY dispense weekly	-	14-Feb-2018	-	30-Jul-2024

Recent medication (Any medication issued within last 90 days not shown above)

Course Last

file:///P:/PCTI/DOCMAN7/DATA_S1/Document/DMEDOC01/00018100/01577279.... 13/05/2026

<u>Drug name</u>	<u>BNF code</u>	<u>Formulation</u>	<u>Dosage</u>	<u>Frequency</u>	<u>started</u>	<u>Duration</u>	<u>Prescribed Date</u>
Amoxicillin Capsules 500 mg	-	15 CAPSULE	ONE TO BE TAKEN THREE TIMES A DAY	-	28-May-2024	5 Days	28-May-2024
Lactulose Solution 3.1-3.7 g/5 ml	0106040G0AAAAA	300 ML	THREE 5ML SPOONFULS TO BE TAKEN TWICE A DAY	-	24-May-2024	10 Days	24-May-2024

Clinical warnings

Lifestyle risks
Exercise status: Not Known

Smoking status: Number per day ? (not known)

Alcohol consumption: Units per day ? (not known)

Additional relevant information
Administrative information
Referred By: Registered GP

Social circumstances

Signature of referring doctor (or other professional) Date

KW/AC

30th May 2024

Social Services
Bridgeway House
IRVINE
KA12 8BD

Dear Sir/Madam

Re: Denys Brown, 124c Montgomery Street, Irvine, KA12 8PW, DOB 26/06/70

Thank you for seeing this man with polycythaemia probably due to smoking, inactivity and all his prescription drugs and cannabis use. I have tried to broach a change in life style and maybe Social Services can help by providing social change that is acceptable to him and his partner. I think he is at big risk with a sudden clotting event. I think his quality of life is good and would value your opinion.

Yours faithfully

Dr Kevin Weaver
(GP Locum)

THIRD PARTY COPY

NHS Confidential: Personal data about a patient

**Confidential - Clinical
Information**

Haematology Department
Area Laboratory
Crosshouse Hospital
Kilmarnock
KA2 0BE
01563 827416



www.nhsaaa.net

Dr S McNair
Townhead Surgery
6/8 High Street
Irvine
Ayrshire
KA12 0AY

Our Ref: FC/NG
Hospital No:
Clinic Date: 20/05/2024
Date Dictated: 20/05/2024
Date Typed: 22/05/2024
Enquiries to: Haematology secretaries
Direct Line: 01563 827416
Ext. Number: 27416

Dear Dr McNair,

DENYS BROWN DOB: 26/06/1970 CHI No: 2606703278
124C MONTGOMERY STREET, IRVINE, AYRSHIRE, KA12 8PW

I saw this man as a new patient in the Haematology Clinic on the 20th May 2024. He has been referred with an elevated haemoglobin and haematocrit and a raised MCV. Blood tests taken in February showed haemoglobin 188 g/l, haematocrit 0.54%, and an MCV of 110 fL with an otherwise normal full blood count. He is a smoker of cannabis and in his own words "quite a heavy smoker" although does not use much tobacco. He is a previous IV drug user who is now on a methadone program. He does not drink alcohol. His main issue is shortness of breath on exertion although he does have ongoing issues with back pain and he mentions that he has recently been seen at your practice because of PR bleeding.

In clinic today he was cyanosed and oxygen saturation at rest was only 86 – 88%. This is by far the most likely cause of his elevated Hb and Hct. I have explained this to him today and encouraged him to cut back on smoking as much as he can to reduce the risk of complications. It is probably worth while looking at his chest to see if this can be optimised, now I will leave this to you to arrange possible Respiratory referral if you feel it is appropriate. His haematocrit on today's bloods has risen to 0.62 and MCV has improved to 102 fl following folate replacement. Evidence for intervention in secondary polycythaemia is really only based on symptomatic polycythaemia not on blood results but a haematocrit of 0.62 is concerning.

I have sent JAK to an epo level for completeness today but fully suspect these to be normal. I have not arranged follow-up but will write to Mr Brown once I have the results of his investigations.

Yours sincerely

Authorised on 22/05/2024 18:15:19 by Fiona Cutler.

Dr. Fiona Cutler
Consultant Haematologist
GMC: 3564949

www.nhsayrshireandarran.com



NHS Confidential. Personal data about a patient



West of Scotland Genetic Services
 Laboratory Genetics
 Level 2B, Laboratory Medicine
 Queen Elizabeth University Hospital
 1345 Govan Road, Glasgow G51 4TF
 Email: genetiqlabs@ggc.scot.nhs.uk Tel: 0141 354 9300



Head of laboratory: Paul Westwood

Molecular Genetics Report for Myeloproliferative Neoplasms

Biochemistry Department
 Area Laboratory
 University Hospital Crosshouse
 Kilmarnock Road
 Kilmarnock
 KA2 0BE

*Cutler
 Haem*

Report Number: 270396

Reported: Lorraine Cowan

Authorised: Anne Lowe

Name of Patient:	Denys BROWN		Date of Birth:	26/06/1970
CHINHS Number:	2606703278	Sex:	Male	
Hospital Number:		Sample Type:	EDTA blood	
Pedigree Number:		Lab Number:	3247954	
Ref Lab Number:	24B757174	Gestation:	Date of Sample:	20/05/2024
			Date Received:	21/05/2024
			Date of Activation:	21/05/2024
			Date of Report:	11/06/2024

Reason for referral: Patient is being investigated for a possible Myeloproliferative Neoplasm.

Conclusion: JAK2 variant c.1849G>T p.(Val617Phe) NOT detected.

Results and interpretation:

Testing of DNA from this patient did not detect the pathogenic JAK2 variant c.1849G>T p.(Val617Phe).

This result does not support a diagnosis of a Myeloproliferative Neoplasm in this patient.

This result should be interpreted in the context of all clinical, morphological, and haematological findings.

Comments:

This assay will only detect the presence or absence of the c.1849G>T p.(Val617Phe) variant and can not detect other molecular causes of Myeloproliferative Neoplasms.

In order to avoid error and/or misinterpretation, transcription of the content of this report is not advised; Laboratory Genetics do not take any responsibility for the accuracy of any data/text transcribed from this report.

Technical Information:

Allele specific PCR to detect the JAK2 variant c.1849G>T p.(Val617Phe) was performed. We estimate that the level of detection for the tests performed is >5%. Reference: Bench et al, British Journal of Haematology, 2012, 160, 25-34.

*Copy + GP please
 [Signature]*



Report Number: 270396

ver 240524

Page 1 of 1

NHS Confidential: Personal data about a patient

Mental Health Services

Addictions
Caley Court Resource Centre
Moorpark Road West
Stevenston
KA20 3HU
www.nhsaaa.net

**CLINICAL IN CONFIDENCE**

Dr. S. McNair
 Townhead Surgery
 6/8 High Street
 Irvine
 Ayrshire
 KA12 0AY

Clinic Date: 25/04/2024
 Date Dictated: 26/04/2024
 Date Typed: 26/04/2024
 Our Ref: CVW/EM
 Enquiries to: Emma Melville
 Tel No: 01294476195

Dear Dr. McNair,

DENYS BROWN
 CHI No: 2606703278

124C MONTGOMERY STREET, IRVINE, KA12 8PW

Diagnosis: 6C43.2 – Opioid Dependence Syndrome
 6C44.2 – Sedative Dependence Syndrome (Benzodiazepines)

Psychiatric Medication: Prescribed by Addiction Services
 Methadone 85ml, daily, weekly dispense
 Diazepam 30mg, daily

Prescribed by General Practitioner
 Quetiapine 100mg, daily
 Pregabalin, dose unconfirmed

Recommendations/Plan: 1. No change to management
 2. Ongoing support from key worker
 3. Outpatient clinic review in six months

I reviewed Mr. Brown in my outpatient clinic at Ballot Road Health Centre on 25th April 2024. He did not report any issues with stability on his medication, and denied any illicit drug use or regular alcohol use. He seemed to have coped relatively well with the reduction to 85ml, but wanted to revisit further reductions at his next appointment to give himself more time to adjust. He did not report any significant changes to his mental health. He described finding it difficult to get out of the house, and said he tends to stay at home. We spoke about the possibility of supporting him with graded exposure, for example – he said he would consider this, but at the moment felt that there were some other stressors that would limit his ability to engage with this. He mentioned some social stressors, including an ongoing difficult relationship with his dad and his sister, but he does have good support from his ex-partner and his son. We did not make any other changes to his treatment, and I will see him again in clinic in due course.

Yours sincerely,

NHS Confidential: Personal data about a patient

2 (CHI No: 2606703278) DENYS BROWN

Authorised on 29/04/2024 13:59:56 by C Woolston.

DR. C. WOOLSTON
Consultant Psychiatrist
NHS Addiction Services (North)

CC: Ms. Linda Thornton, NADARS, Caley Court Resource Centre, Stevenston, KA23 3HU

THIRD PARTY COPY

www.nhsaaa.net



Hospital use only	Clinic	Day Date	Time	Hospital No.
-------------------	--------	----------	------	--------------

Transport required?

Unique Care Pathway Number: 1010331985187

REFERRAL LETTER
MEDICAL IN CONFIDENCE

CHI:2606703278

REFERRAL TO	
Respiratory MedicineAQ AA Respiratory	Ethnic Origin (White) Scottish
University Hospital Crosshouse Kilmarnock Road Kilmarnock Ayrshire KA2 0BE	Language interpreter req'd - Religion - Religious Observance - Vision impairment - Hearing impairment - Sign language interpreter req'd. -
Urgency of referral	Routine
Date of referral	30-May-2024
Date submitted	30-May-2024

PATIENT DETAILS		Patient's address
Surname	Brown	124c Montgomery Street Irvine KA12 8PW
Forename(s)	Denys	
Title	-	
Sex	Male	
Date of birth	26-Jun-1970	Contact number(s)
CHI no.	2606703278	-

REGISTERED GP DETAILS		Practice address
Name	Dr Duncan Renfrew	6/8 High Street Irvine
GMC code	6163146	Contact number(s)
GP code	21181	
Practice name	Townhead Surgery	
Practice code	80344	Voice: 01294 441441 Facsimile: 01294 312832

REFERRING PRACTITIONER DETAILS		Practice address
Name	Dr Kevin Weaver (GP Locum)	6/8 High Street Irvine AYRSHIRE KA12 0AY
GMC code	2617365	Contact number(s)
GP code	-	
Practice name	Townhead Surgery (80344)	
Practice code	80344	Voice: 01294 441 441

file:///P:/PCTI/DOCMAN7/DATA_S1/Document/DMEDOC01/00018100/01561947.... 13/05/2026

CLINICAL INFORMATION**History of presenting complaint / examination findings / investigation results****Presenting complaint**

Description: see below

Comment: Dictated 24/05/24 ac

Thank you for seeing this man with polycythaemia probably due to smoking, inactivity and all his prescription drugs and cannabis use. I have tried to broach a change in life style and maybe Social Services can help by providing social change that is acceptable to him and his partner. I think he is at big risk with a suddenly clotting event and wonder if some medication to prevent this is worth considering. I think his quality of life is good and would value your opinion.

Examinations and Investigations

Height: 184 -
 Weight(kg): 110 -
 BMI: 32.49 -
 Light smoker - 1-9 cigs/day: Smoker\$.clm - Repeat after an Interval 31-Dec-2009 00:00
 Current smoker: Smoker\$.clm - Repeat after an Interval 23-Nov-2006 00:00
 Moderate smoker - 10-19 cigs/d: Disease: New Patient Townhead, priority=2 31-Aug-2006 00:00
 Current smoker: Smoker\$.clm - Repeat after an Interval 31-Aug-2006 00:00
 Teetotaler: Disease: New Patient Townhead, priority=2 31-Aug-2006 00:00
 Avoids even trivial exercise: Disease: New Patient Townhead, priority=2 31-Aug-2006 00:00

Reason for referral

Care type requested: Out Patient

Expected outcome: Not Specified

Past medical history**Pre-existing conditions**

Description	Laterality	Modifier	Extension	Date of onset	Recorded Date
Query Gallstones	Uncertain	-	re US Abdomen result recd 27/10/17. [Further scan to be done]	20-Oct-2017	20-Oct-2017
Drug addiction	-	-	Disease: New Patient Townhead, Cannabis and diazepam	30-Jul-2002	30-Jul-2002
Stabbed in fight	-	-	Disease: New Patient Townhead, Left chest wall	10-Jul-2000	10-Jul-2000
[X]Assault	-	-	Disease: New Patient Townhead,	10-Jul-2000	10-Jul-2000
Anxiety with depression	-	-	Disease: New Patient Townhead,	05-Jul-2000	05-Jul-2000
Nondependent abuse of drugs	-	-	Disease: New Patient Townhead, Heroin	06-Jun-2000	06-Jun-2000
Drug addiction	-	-	Disease: New Patient Townhead,	30-Jan-1996	30-Jan-1996
Closed fracture of radius (alone), unspecified	-	-	Disease: New Patient Townhead, Left	04-Aug-1982	04-Aug-1982
Acute Bronchitis	-	-	Disease: New Patient Townhead, Admitted	25-Feb-1971	25-Feb-1971

Past procedures

Description	Laterality	Modifier	Comments	Date performed	Recorded Date
Medication reconciliation	-	-	Prescribed Elsewhere	02-Sep-2022	02-Sep-2022
Medication reconciliation	-	-	Prescribed elsewhere	07-Jan-2022	07-Jan-2022
Medication reconciliation	-	-	Prescribed elsewhere	07-Jan-2022	07-Jan-2022
Medication reconciliation	-	-	Prescribed Elsewhere	22-Nov-2021	22-Nov-2021
Medication reconciliation	-	-	prescribed elsewhere	18-Nov-2020	18-Nov-2020
Medication reconciliation	-	-	Prescribed elsewhere	20-May-2020	20-May-2020

file:///P:/PCTI/DOCMAN7/DATA_S1/Document/DMEDOC01/00018100/01561947.... 13/05/2026

Medication reconciliation	-	-	Prescribed elsewhere	14-May-2020	14-May-2020
Medication reconciliation	-	-	Prescribed elsewhere	25-Jul-2017	25-Jul-2017
Medication reconciliation	-	-	Prescribe elsewhere	29-Dec-2016	29-Dec-2016
Medication reconciliation	-	-	Prescribed Elsewhere	09-Feb-2016	09-Feb-2016
Medication reconciliation	-	-	prescribed elsewhere	26-Nov-2014	26-Nov-2014
Hepatitis C antibody test positive	-	-	Disease: New Patient Townhead,	28-May-1999	28-May-1999
Detoxification dependence drug	-	-	Disease: New Patient Townhead,	30-Jan-1996	30-Jan-1996

Current medication (Active Repeat medication issued within the last 12 months)

Drug name	BNF code	Formulation	Dosage	Frequency	Course started	Duration	Last Prescribed Date
Omeprazole Capsules (Gastro-Resistant) 20 mg	0103050P0AAAGAG	28 CAPSULE	ONE TO BE TAKEN EACH DAY	-	02-Sep-2021	-	08-May-2024
Pregabalin Capsules 150 mg	-	84 CAPSULE	ONE TO BE TAKEN THREE TIMES A DAY	-	29-Jul-2021	-	08-May-2024
Mebeverine Hydrochloride Tablets 135 mg	0102000P0AAAABAB	100 TABLET	ONE TO BE TAKEN THREE TIMES A DAY 20 MINUTES BEFORE MEALS	-	14-Mar-2019	-	08-May-2024
Meloxicam Tablets 15 mg	1001010AAAAABAB	30 TABLET	ONE TO BE TAKEN DAILY	-	03-Jul-2018	-	08-May-2024
Quetiapine Fumarate Tablets 200 mg	0402010ABAAADAD	28 tablet	1 Tab DAILY dispense weekly	-	14-Feb-2018	-	08-May-2024

Recent medication (Any medication issued within last 90 days not shown above)

Drug name	BNF code	Formulation	Dosage	Frequency	Course started	Duration	Last Prescribed Date
Amoxicillin Capsules 500 mg	-	15 CAPSULE	ONE TO BE TAKEN THREE TIMES A DAY	-	28-May-2024	5 Days	28-May-2024
Salbutamol Cfc-free inhaler 100 micrograms/puff	0301011R0AAAPAP	1 INHALER	ONE TO TWO PUFFS TO BE INHALED AS REQUIRED FOR BREATHLESSNESS	-	28-May-2024	42 Days	28-May-2024
Lactulose Solution 3.1-3.7 g/5 ml	0106040G0AAAAAA	300 ML	THREE 5ML SPOONFULS TO BE TAKEN TWICE A DAY	-	24-May-2024	10 Days	24-May-2024

Clinical warnings

Smoking status

Alcohol consumption

Lifestyle risks

Exercise status: Not Known

Number per day
? (not known)Units per day
? (not known)**Additional relevant information****Administrative information**

Referred By: Registered GP

Social circumstances

file:///P:/PCTI/DOCMAN7/DATA_S1/Document/DMEDOC01/00018100/01561947.... 13/05/2026

NHS Confidential: Personal data about a patient

SOUTH GLASGOW HOSPITALS
 IMMUNOLOGY REPORT
 (Tel 0141 347 8872/0141 354 9337)

IMM1 Run: 402

Surname: **BROWN** Location: Biochemistry *McNAE*
 Forename: **Denys** Crosshouse Hospital *T McNAE*
 DOB/Age: 26.06.70 Sex: Male Kilmarnock
 CHI/Unit No: 2606703278 Ayrshire & Arran H.B.
 Address: Requestor: I Cochrane
 Diagnosis: Ext Labno: 24b752201
 Details:

29 FEB 2024

Lab No: B.24.3521881.E Received: 15.02.24 14:44
 Collected: 13.02.24 Authorised by: Automatic release by sys
 Authorised: 16.02.24

COELIAC SEROLOGY

TTG Ab (IgA) 0.7 U/mL (0.0-7.0)

Specimen	GP/Name	Specimen	GP/Name
✓	NSG		
✓	NSG		

Comments:

I Coeliac Serology: IgA TTG Ab = IgA Tissue Transglutaminase Ab.
 Normal = <7.0, equivocal = 7.0-10.0, positive = >10.0.
 If screening for coeliac disease, this result is only valid if the
 person was eating gluten at least twice a day for previous 6 weeks.
 If known to have coeliac disease,
 this negative result suggests adherence to gluten free diet.
 IgA coeliac serology has reduced sensitivity if total IgA <0.2g/l

Handwritten signature



Date reported: 16.02.24

Page 1 of 3

THIRD PARTY COPY